

Venous neurovascular conflict in trigeminal neuralgia: A case series of developmental venous anomalies

Pavel I. Trukhachev¹✉, Elena A. Filimonova^{1,2}

¹Federal Neurosurgical Center, Nemirovicha-Danchenko str., 132/1, Novosibirsk, Russian Federation, 630087

²Novosibirsk State Medical University, Krasny ave., 52, Novosibirsk, Russia, 630091

Abstract

While arterial compression is the predominant cause of trigeminal neuralgia, venous etiologies remain poorly characterized. Developmental venous anomalies (DVA) are generally regarded as benign incidental findings but may occasionally result in symptomatic neurovascular conflict. We report a case series of four patients with trigeminal neuralgia attributed to developmental venous anomalies, focusing on imaging features, underlying pathophysiological mechanisms, and surgical management.

All patients underwent brain magnetic resonance imaging (MRI) using a standardized cranial nerve protocol. MRI demonstrated DVAs with direct venous contact or compression of the trigeminal nerve root entry zone, sometimes associated with nerve thinning, complex venous networks, or altered venous drainage due to chronic venous outflow obstruction. Microvascular decompression was performed using tailored, vein-preserving approaches.

Postoperative pain relief was achieved in all four patients; however, postoperative sensory deficits and late pain recurrence were observed in individual cases. These findings indicate that DVAs can represent a rare but clinically relevant cause of trigeminal neuralgia. Advanced MRI plays a pivotal role in diagnosis and surgical planning, and recognition of venous neurovascular conflict is essential, particularly in younger patients with atypical imaging findings.

Keywords: developmental venous anomalies, MRI, trigeminal neuralgia

For citation: Trukhachev P.I., Filimonova E.A. Venous neurovascular conflict in trigeminal neuralgia: A case series of developmental venous anomalies. *Sibneuro*. 2026;2(1):69–76. <https://doi.org/10.64265/3033-649X-2026.2.1.69-76>

Authors' contribution

Trukhachev P.I. – conceptualization, methodology, formal analysis, investigation, writing – original draft. Filimonova E.A. – investigation, writing – review & editing, supervision.

Conflict of interest. The authors declare no conflict of interest.

Financial disclosure. The study was carried out without any financial support.

Use of AI. No AI technologies were used in the writing of this article.

Data availability. The data is available upon reasonable request to the corresponding author

Received: 23.12.2025

Accepted: 11.02.2026

Published: 15.03.2026

Венозный нейроваскулярный конфликт в патогенезе тригеминальной невралгии: клинические наблюдения аномалий развития венозной системы

Трухачев П.И.¹✉, Филимонова Е.А.^{1,2}

¹Федеральный центр нейрохирургии Минздрава России, ул. Немировича-Данченко, д. 132/1, г. Новосибирск, Российская Федерация, 630087

²Новосибирский государственный медицинский университет Минздрава России, Красный просп., д. 52, г. Новосибирск, Российская Федерация, 630091

Резюме

Хотя артериальная компрессия является преобладающей причиной тригеминальной невралгии, венозная этиология остается недостаточно изученной. Аномалии развития вен (АРВ) обычно рассматриваются как доброкачественные случайные находки, однако в ряде случаев они могут приводить к развитию симптомного нейроваскулярного конфликта. Мы представляем клинические наблюдения четырех пациентов с тригеминальной невралгией, обусловленной аномалиями развития вен, с акцентом на особенности визуализации, лежащие в основе патофизиологические механизмы и хирургическую тактику.

Всем пациентам была выполнена магнитно-резонансная томография (МРТ) головного мозга по стандартизованному протоколу для исследования черепных нервов. МРТ выявила АРВ с не-

посредственным контактом вены или компрессией зоны входа корешка тройничного нерва; в ряде случаев это сочеталось с истончением нерва, наличием сложных венозных сетей или изменением венозного оттока вследствие хронической обструкции. Микроваскулярная декомпрессия выполнялась с использованием индивидуального подхода, с сохранением венозных структур.

Послеоперационное купирование боли было достигнуто у всех четырех пациентов; однако в отдельных случаях наблюдались послеоперационные сенсорные нарушения и поздний рецидив болевого синдрома. Полученные данные свидетельствуют о том, что АРВ могут представлять собой редкую, но клинически значимую причину тригеминальной невралгии. Современная МРТ играет ключевую роль в диагностике и планировании операции, а распознавание венозного нейроваскулярного конфликта имеет важное значение, особенно у молодых пациентов с атипичной картиной по данным визуализации.

Ключевые слова: аномалии развития вен, МРТ, тригеминальная невралгия

Для цитирования: Трухачев П.И., Филимонова Е.А. Венозный нейроваскулярный конфликт в патогенезе тригеминальной невралгии: клинические наблюдения аномалий развития венозной системы. *Сибнейро*. 2026;2(1):69–76. <https://doi.org/10.64265/3033-649X-2026.2.1.69-76>

Вклад авторов

Трухачев П.И. – разработка концепции, методология, формальный анализ, проведение исследования, создание черновика рукописи.

Филимонова Е.А. – проведение исследования, написание рукописи – рецензирование и редактирование научного руководства.

Конфликт интересов. Авторы заявили об отсутствии конфликта интересов.

Финансирование. Исследование проведено без привлечения финансовой поддержки.

Использование ИИ. При написании статьи технологии искусственного интеллекта не использовались.

Доступность данных. Данные доступны по запросу автору, ответственному за переписку

Поступила: 23.12.2025

Принята к печати: 11.02.2026

Опубликована: 15.03.2026

Introduction

Trigeminal neuralgia is characterized by recurrent, paroxysmal episodes of severe, electric shock-like facial pain involving one or more divisions of the trigeminal nerve. Individual attacks typically last from a fraction of a second to up to two minutes. Although relatively uncommon overall, trigeminal neuralgia represents the most frequent cranial neuralgia, with an estimated incidence of approximately 0.3 % [1].

Despite centuries of clinical experience, trigeminal neuralgia remains a diagnostic and therapeutic challenge, and misdiagnosis is not uncommon. The disorder predominantly affects middle-aged and elderly individuals, with a higher prevalence in women and a tendency toward right-sided involvement. In most patients, trigeminal neuralgia is caused by neurovascular compression at the trigeminal nerve root entry zone, most commonly by an arterial loop, whereas venous compression is less frequently observed. Less common secondary causes include vascular malformations, vertebralbasilar dolichoectasia, aneurysms, cerebellopontine angle tumors, and demyelinating lesions in multiple sclerosis [1].

Developmental venous anomalies (DVAs) represent a rare cause of trigeminal neuralgia. DVAs are considered variants of normal venous development rather than true vascular malformations and are frequently detected as in-

cidental findings on contrast-enhanced magnetic resonance imaging (MRI), with a reported prevalence of 3–9 %. While typically asymptomatic, DVAs have been associated with other intracranial pathologies, including cavernous malformations, arteriovenous malformations, hemorrhage, and epileptic seizures. Advances in high-resolution MRI now allow detailed visualization of the relationship between DVAs and adjacent cranial nerves, including the trigeminal nerve [2].

The present case series describes patients with trigeminal neuralgia in whom a developmental venous anomaly was identified as the presumed offending structure. We summarize the clinical presentation, imaging characteristics, and intraoperative findings in these patients and assess the role, safety, and limitations of microvascular decompression for symptom control in this uncommon etiology of trigeminal neuralgia.

Case series presentation

The following case series illustrates the imaging features of trigeminal neuralgia associated with developmental venous anomalies. All patients underwent brain MRI using a standardized cranial nerve protocol. High-resolution heavily T2-weighted three-dimensional sequences (3D DRIVE) were acquired for detailed

visualization of the trigeminal nerve, root entry zone, and adjacent cerebrospinal fluid spaces. Time-of-flight MR angiography (TOF-MRA) was performed to evaluate arterial anatomy and to assess for arterial neurovascular conflict. Contrast-enhanced T1-weighted imaging was obtained to characterize venous structures and to identify developmental venous anomalies, including their morphology, drainage pattern, and spatial relationship to the trigeminal nerve. Susceptibility-weighted imaging (SWI) was additionally acquired to improve detection of venous structures and associated susceptibility changes and to assess for concomitant cavernous malformations or microhemorrhages. Imaging findings were reviewed with particular attention to nerve-vessel contact or compression at the root entry zone.

Case 1

A 15-year-old female patient had experienced trigeminal neuralgia for three years. The initial symptoms consisted of sharp, paroxysmal pain involving the second division of the trigeminal nerve on the left side, radiating to the frontal region. The patient was initially evaluated by a dentist, and dental sanitation resulted in temporary symptom resolution. Three years later, she developed a nocturnal recurrence of sharp facial pain lasting approximately one minute, with a similar distribution. Non-steroidal anti-inflammatory drugs prescribed by a neurologist were ineffective. Two weeks later, the patient was hospitalized, and trigeminal neuralgia was correctly diagnosed. Treat-

ment with carbamazepine and gabapentin provided only partial symptom control. Two months thereafter, the patient experienced an episode of loss of consciousness and was referred to our institution for further evaluation.

Brain MRI demonstrated a caput medusae pattern in the left cerebellar hemisphere, consistent with a developmental venous anomaly. A large draining vein was identified coursing between the pons and the cerebellar hemisphere and draining into the superior petrosal sinus. This vein was located lateral to the trigeminal nerve root entry zone without evidence of direct compression. However, an additional smaller venous structure was visualized in close proximity to the cranial surface of the trigeminal nerve at the root entry zone. Figure 1 illustrates the main MRI findings.

Teflon pads were interposed between the pons and the cerebellar hemisphere to separate the neurovascular structures. Postoperatively, the patient achieved complete pain relief without new neurological deficits.

Case 2

A 38-year-old man presented with severe, shooting pain on the right side of the face, triggered by minimal stimulation. The trigger zone was located in the maxillary region, corresponding to the second division of the trigeminal nerve. Pain episodes lasted up to two minutes. The patient initially consulted a dentist and underwent extraction of several teeth. He was subsequently diagnosed with trigeminal neuralgia by a neurologist and treated with

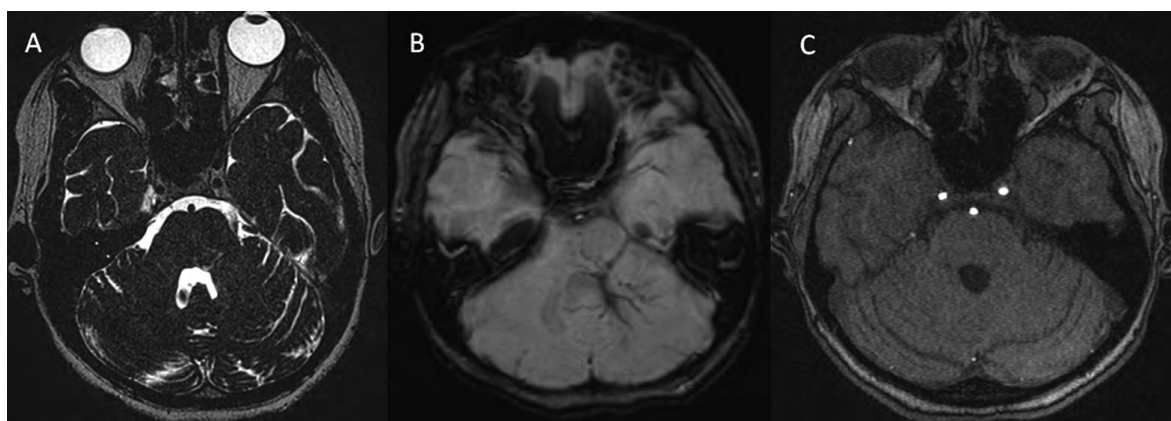


Figure 1. MRI findings in Case 1: A – 3D-DRIVE image showing a dilated venous structure in the left cerebellopontine angle adjacent to the root entry zone of the left trigeminal nerve; B – SWI demonstrating a dilated vein in the left middle cerebellar peduncle and a “caput medusae” pattern in the left cerebellar hemisphere and pons; C – 3D-TOF MR angiography showing no arterial neurovascular conflict around the left trigeminal nerve. Source: created by the authors

Рисунок 1. Данные МРТ в наблюдении 1: А – 3D-DRIVE-изображение, демонстрирующее расширенную венозную структуру в области левого мостомозжечкового угла, прилежащую к зоне входа корешка левого тройничного нерва; Б – изображение, взвешенное по магнитной восприимчивости (SWI), визуализирующее расширенную вену в левом среднем мозжечковой ножке и паттерн «головы медузы» в левом полушарии мозжечка и мосту; В – 3D-TOF МР-ангиография, демонстрирующая отсутствие артериального нейроваскулярного конфликта в области левого тройничного нерва. Источник: составлено авторами

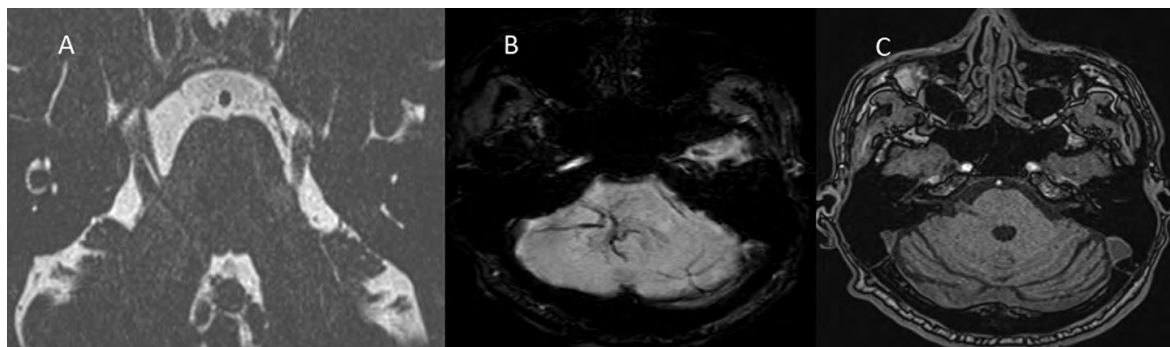


Figure 2. MRI findings in Case 2: A – 3D-DRIVE image showing a dilated venous structure in the right cerebellopontine angle compressing the cisternal segment of the right trigeminal nerve; B – SWI demonstrating a “caput medusae” pattern in the right cerebellar hemisphere and middle cerebellar peduncle; C – 3D-TOF MR angiography showing no arterial neurovascular conflict around the right trigeminal nerve. Source: created by the authors

Рисунок 2. Данные МРТ в наблюдении 2: А – 3D-DRIVE-изображение, демонстрирующее расширенную венозную структуру в области правого мостомозжечкового угла, компремирующую цистернальный сегмент правого тройничного нерва; Б – изображение, взвешенное по магнитной восприимчивости (SWI), демонстрирующее паттерн «головы медузы» в правом полушарии мозжечка и правой средней мозжечковой ножке; В – 3D-TOF МР-ангиография, показывающая отсутствие артериального нейроваскулярного конфликта в области правого тройничного нерва. Источник: составлено авторами

carbamazepine for five years, achieving good symptom control.

Although the patient had been pain-free for the preceding two years, MRI was recommended during neurosurgical consultation. Imaging demonstrated a caput medusae pattern in the right cerebellar hemisphere, consistent with a DVA. A large collecting vein was identified within the right cerebellopontine angle, causing significant compression of the trigeminal nerve root entry zone on its lateral aspect, corresponding to Sindou grade 3 neurovascular conflict. On high-resolution imaging, the affected trigeminal nerve appeared approximately half the thickness of the contralateral nerve. Figure 2 illustrates the main MRI findings.

Microvascular decompression was performed via a retromastoid lateral cerebellar approach. Intraoperatively, the draining vein was found to compress the trigeminal nerve dorsolaterally and was gently mobilized superiorly and laterally. A Teflon felt was interposed between the nerve and the vein. Postoperatively, the patient remained pain-free for three years but developed facial numbness.

After three years, the patient experienced recurrence of severe facial pain (visual analog scale score of 10). Imaging and clinical correlation suggested granulomatous tissue formation near the root entry zone. Reoperation was recommended; however, the patient declined further surgical treatment.

Case 3

A 40-year-old female patient presented with shock-like pain on the right side of the face, triggered by light tactile stimula-

tion, such as touching or washing the face. Trigeminal neuralgia was diagnosed, and the patient was treated with carbamazepine for ten years. During the year preceding presentation, her symptoms progressively worsened.

Contrast-enhanced MRI demonstrated a dilated venous structure within the right middle cerebellar peduncle associated with a complex venous network in the right cerebellar hemisphere, draining into the right superior petrosal sinus, consistent with a DVA. The visible venous segment originated at the trigeminal nerve root entry zone and caused severe compression of the cisternal portion of the trigeminal nerve. Figure 3 illustrates the main MRI findings.

Microvascular decompression was performed with careful consideration of venous anatomy. Intraoperatively, coagulation of the vein was avoided because of its large diameter and the associated risk of venous infarction. The vein was meticulously dissected from the dorsal surface of the trigeminal nerve root, extending from the brainstem to the mid-point of the cisternal segment. Adequate decompression was achieved along the entire course of the nerve from the pons to the cisternal portion. Spongostan fragments were interposed between the nerve and the vein; Teflon was not used.

Postoperatively, the patient was pain-free and exhibited no new neurological deficits. However, she was subsequently lost to follow-up.

Case 4

A 46-year-old male patient presented with constant and paroxysmal shooting pain on the left side of the face, triggered by light

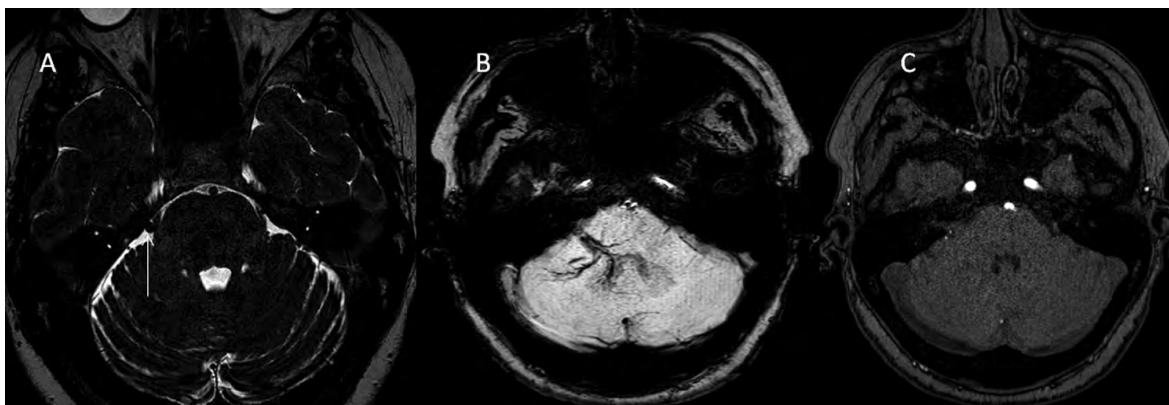


Figure 3. MRI findings in Case 3: A – 3D-DRIVE image showing a dilated venous structure (white arrow) in the right cerebellopontine angle compressing the root entry zone of the right trigeminal nerve; B – SWI showing a dilated vein and a “caput medusae” pattern in the right cerebellar hemisphere and middle cerebellar peduncle; C – 3D-TOF MR angiography showing no arterial neurovascular conflict around the right trigeminal nerve. Source: created by the authors

Рисунок 3. Данные МРТ в наблюдении 3: А – 3D-DRIVE-изображение, показывающее расширенную венозную структуру в области правого мостомозжечкового угла, компрессирующую зону входа корешка правого тройничного нерва; Б – изображение, взвешенное по магнитной восприимчивости (SWI), демонстрирующее расширенную вену и паттерн «головы медузы» в правом полушарии мозжечка и правой средней мозжечковой ножке; В – 3D-TOF МР-ангиография, не выявляющая артериального нейроваскулярного конфликта в области правого тройничного нерва. Источник: составлено авторами

touch, speaking, shaving, or eating. Symptoms had begun approximately eight years earlier following extraction of a mandibular tooth. Classical trigeminal neuralgia involving the second and third divisions of the trigeminal nerve was diagnosed, and the patient was treated with carbamazepine.

Brain MRI demonstrated a dilated draining vein within the left cerebellar hemisphere and adjacent brainstem, consistent with a developmental venous anomaly. In addition, postcontrast images revealed chronic thrombosis of the left transverse sinus, with imaging features suggestive of long-standing venous

outflow alteration. The coexistence of altered venous drainage due to chronic transverse sinus thrombosis likely contributed to venous engorgement and neurovascular compression in this case. Figure 4 illustrates the main MRI findings.

Microvascular decompression was performed. Intraoperatively, one of the large tributaries of the vein of Dandy, suspected to compress the trigeminal nerve root near the pons along its dorsal surface, was coagulated and divided. Additionally, the anterior inferior cerebellar artery was dissected from the inferior margin of the trigeminal nerve and sep-

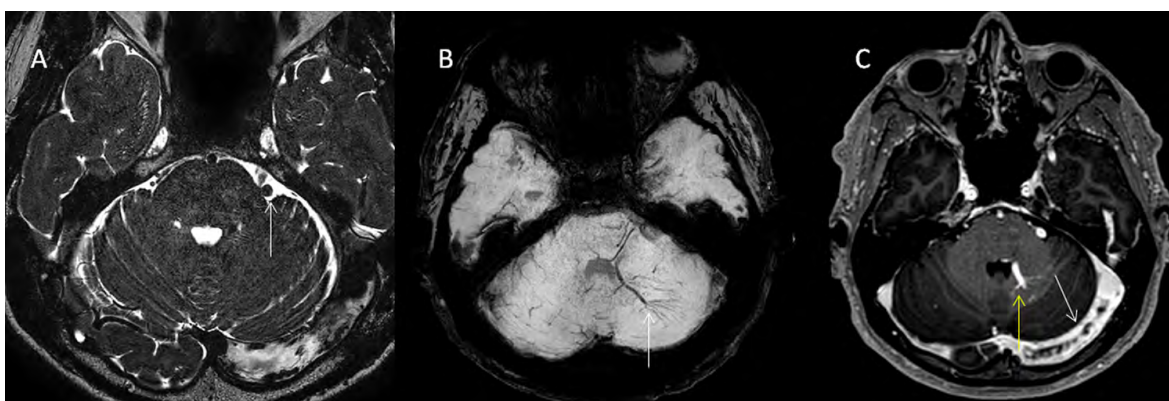


Figure 4. MRI findings in Case 4: A – 3D-DRIVE image showing a dilated venous structure (white arrow) in the left cerebellopontine angle compressing the root entry zone of the left trigeminal nerve; B – SWI demonstrating a “caput medusae” pattern in the left cerebellar hemisphere (white arrow); C – post-contrast T1-weighted image showing a dilated vein in the left middle cerebellar peduncle (yellow arrow) and chronic thrombosis of the left transverse sinus (white arrow). Source: created by the authors

Рисунок 4. Данные МРТ в наблюдении 4: А – 3D-DRIVE-изображение, демонстрирующее расширенную венозную структуру (белая стрелка) в области левого мостомозжечкового угла, компрессирующую зону входа корешка левого тройничного нерва; Б – изображение, взвешенное по магнитной восприимчивости (SWI), демонстрирующее паттерн «головы медузы» в левом полушарии мозжечка (белая стрелка); В – T1-взвешенное изображение с контрастным усилением, показывающее расширенную вену в левой средней мозжечковой ножке (желтая стрелка) и хронический тромбоз левого поперечного синуса (белая стрелка). Источник: составлено авторами

arated using a Teflon pad. In the early post-operative period, edema developed in the left cerebellar hemisphere without imaging evidence of infarction.

The key imaging findings, venous drainage characteristics, and corresponding surgical strategies across all cases are summarized in Table 1.

Discussion

Trigeminal neuralgia associated with developmental venous anomalies represents a rare but clinically important subtype of neurovascular conflict. In contrast to classical trigeminal neuralgia, which predominantly affects middle-aged and elderly patients and is most often caused by arterial compression at the root entry zone (REZ), venous angiomas and DVAs tend to present at a significantly younger age. This observation has been consistently reported in previous case reports and small series and is corroborated by our findings [3–6].

The REZ is particularly vulnerable because it represents a transitional zone between central and peripheral myelin. Chronic venous contact may result in focal demyelination, ephaptic transmission, and increased excitability

of trigeminal afferents. Venous anomalies may exert continuous low-pressure compression or tethering of the nerve, and anomalous drainage patterns – such as transpontine or trans-mesencephalic veins – may further distort the nerve or adjacent brainstem structures.

Microvascular decompression remains the most effective surgical treatment for trigeminal neuralgia, providing durable pain relief without intentional injury to the nerve. However, outcomes appear less favorable in cases of venous compression compared with arterial conflicts. One explanation is that venous structures often represent essential drainage pathways for the brainstem or cerebellum and cannot be safely sacrificed. Coagulation or division of a major draining vein may result in venous congestion, edema, or infarction. Consequently, decompression in venous cases often relies on gentle mobilization and interposition techniques rather than vessel sacrifice, as reflected by the heterogeneous surgical strategies employed across our cases (Table 1) [3, 7, 8].

Advanced neuroimaging plays a pivotal role in the management of these patients. High-resolution MRI, TOF-MRA, susceptibility-weighted imaging, and MR venography allow precise delineation of venous anatomy, drainage pat-

Table 1. Clinical, imaging, and surgical characteristics of patients with trigeminal neuralgia associated with developmental venous anomalies in our case series. Source: created by the authors

Таблица 1. Клинико-визуализационные и хирургические характеристики пациентов с тригеминальной невралгией, ассоциированной с аномалиями развития вен, в нашей серии наблюдений. Источник: составлено авторами

Case	Clinical summary	Key MRI findings	Neurovascular conflict and surgery	Outcome/follow-up
1	15/F Left; V2	DVA (“caput medusae”) in left cerebellar hemisphere. Large draining vein to superior petrosal sinus. Small venous branch contacting the trigeminal REZ.	NVC: venous contact at cranial REZ (small vein). MVD: Teflon interposition between the pons and cerebellar hemisphere.	Complete pain relief. No neurological deficits.
2	38/M Right; V2	DVA (“caput medusae”) in right cerebellar hemisphere. Large collecting vein in CPA.	NVC: significant venous compression of the REZ (Sindou III); nerve thinning. MVD: venous mobilization + Teflon felt interposition.	Pain-free 3 years. Facial numbness. Late recurrence.
3	40/F Right; V2–V3	Dilated vein in right middle cerebellar peduncle. Complex venous network draining to the superior petrosal sinus.	NVC: severe venous compression of the REZ and cisternal segment. MVD: extensive venous dissection; Spongostan interposition (no Teflon).	Pain-free. No neurological deficits. Lost to follow-up.
4	46/M Left; V2–V3	Dilated draining vein in left cerebellar hemisphere and brainstem (tributary of the vein of Dandy). Chronic left transverse sinus thrombosis (long-standing outflow alteration).	NVC: combined venous + arterial (AICA) compression. MVD: coagulation/division of venous tributary + AICA decompression with Teflon.	Postoperative cerebellar edema. No infarction.

Note: F – female; CPA – cerebellopontine angle; REZ – root entry zone; MVD – microvascular decompression; NVC – neurovascular conflict; AICA – anterior inferior cerebellar artery

Примечание: F – female; CPA – cerebellopontine angle; REZ – root entry zone; MVD – microvascular decompression; NVC – neurovascular conflict; AICA – anterior inferior cerebellar artery

terns, and their relationship to the trigeminal nerve. Classic neuroradiological studies have demonstrated that many posterior fossa venous angiomas drain through critical transpontine or transmesencephalic veins, emphasizing the importance of detailed preoperative venous mapping to avoid catastrophic complications [9].

Venous pathology associated with chronic venous thrombosis also deserves consideration. Chronic cerebral venous thrombosis may lead to venous hypertension and post-thrombotic remodeling, with formation of dilated collateral veins capable of compressing cranial nerves. In such cases, neuralgia arises not from the thrombus itself but from secondary venous alterations. In the present series, this mechanism is illustrated by Case 4, in which chronic thrombosis of the left transverse sinus was identified, providing a plausible anatomical substrate for secondary venous compression of the trigeminal nerve [10, 11].

Previously reported cases of trigeminal neuralgia associated with venous angiomas, together with the current series, are summarized in Supplementary Table 1, adapted from the literature review by M. Samadian et al. [3] and expanded to include the additional cases presented in this study. This combined overview highlights the heterogeneity of venous anatomy, drainage patterns, and neurovascular relationships implicated in venous trigem-

inal neuralgia and underscores the variability in surgical strategies and clinical outcomes reported across the literature.

This study is limited by its small sample size and retrospective nature. Larger prospective series and multicenter imaging registries are required to better define prognostic factors, refine imaging-based classification, and optimize surgical strategies for trigeminal neuralgia associated with developmental venous anomalies.

Conclusion

Trigeminal neuralgia associated with developmental venous anomalies represents a distinct and uncommon subtype of neurovascular conflict, characterized by early disease onset, a prolonged clinical course, and increased surgical complexity. Unlike arterial compression, venous conflicts often involve functionally significant draining veins that cannot be safely sacrificed without risking venous congestion or infarction; therefore, careful preoperative venous imaging is essential.

Microvascular decompression can provide effective pain relief in selected patients when meticulous, vein-preserving surgical strategies are employed. Early recognition of venous etiologies and timely referral for surgical evaluation may improve outcomes in this predominantly young patient population.

References

1. Nurmikko TJ, Eldridge PR. Trigeminal neuralgia – Pathophysiology, diagnosis and current treatment. *Br J Anaesth*. 2001; 87(1): 117-132. <https://doi.org/10.1093/bja/87.1.117>
2. Aoki R, Srivatanakul K. Developmental venous anomaly: Benign or not benign. *Neurol Med Chir (Tokyo)*. 2016; 56(9): 534-543. <https://doi.org/10.2176/NMC.RA.2016-0030>
3. Samadian M, Bakhtevvari MH, Nosari MA, Babadi AJ, Razaeei O. Trigeminal neuralgia caused by venous angioma: A case report and review of the literature. *World Neurosurg*. 2015; 84(3): 860-864. <https://doi.org/10.1016/J.WNEU.2015.04.063>
4. Peterson AM, Williams RL, Fukui MB, Meltzer CC. Venous angioma adjacent to the root entry zone of the trigeminal nerve: Implications for management of trigeminal neuralgia. *Neuroradiology*. 2002; 44(4): 342-346. <https://doi.org/10.1007/S00234-001-0724-4/METRICS>
5. Nagata K, Nikaido Y, Yuasa T, Fujioka M, Ida Y, Fujimoto K. Trigeminal neuralgia associated with venous angioma – Case report. *Neurol Med Chir (Tokyo)*. 1995; 35(5): 310-313. <https://doi.org/10.2176/NMC.35.310>
6. Yamamoto T, Suzuki M, Esaki T, Nakao Y, Mori K. Trigeminal neuralgia caused by venous angioma – Case report. *Neurol Med Chir (Tokyo)*. 2013; 53(1): 40-43. <https://doi.org/10.2176/NMC.53.40>
7. Barker FG, Jannetta PJ, Bissonette DJ, Larkins MV, Jho HD. The long-term outcome of microvascular decompression for trigeminal neuralgia. *N Engl J Med*. 1996; 334(17): 1077-1084. <https://doi.org/10.1056/NEJM199604253341701;PAGEGROUP:STRING:PUBLICATION>
8. Broggi G, Ferroli P, Franzini A, Servello D, Dones I. Microvascular decompression for trigeminal neuralgia: Comments on a series of 250 cases, including 10 patients with multiple sclerosis. *J Neurol Neurosurg Psychiatry*. 2000; 68(1): 59-64. <https://doi.org/10.1136/jnnp.68.1.59>
9. Damiano TR, Truwit CL, Dowd CF, Symonds DL, Portela L, Dreisbach J. Posterior fossa venous angiomas with drainage through the brain stem. *AJNR Am J Neuroradiol*. 1994; 15(4): 643-652.
10. Ferro JM, Canhão P, Stam J, Boussier MG, Barinagarrementeria F; ISCVT Investigators. Prognosis of cerebral vein and dural sinus thrombosis: Results of the International Study on Cerebral Vein and Dural Sinus Thrombosis (ISCVT). *Stroke*. 2004; 35(3): 664-670. <https://doi.org/10.1161/01.STR.0000117571.76197.26>
11. Luo Y, Tian X, Wang X. Diagnosis and treatment of cerebral venous thrombosis: A review. *Front Aging Neurosci*. 2018; 10(JAN): 319053. <https://doi.org/10.3389/FNAGI.2018.00002/FULL>

Supplementary Table 1. Venous etiologies of trigeminal neuralgia: published cases and the present series (literature reports)

Дополнительная таблица 1. Венозные этиологические факторы тригеминальной невралгии: опубликованные случаи и настоящая серия наблюдений (данные литературы)

Source	Patient (age/sex)	Offending venous lesion (type/key location)	Side	Management	Technical note	Clinical result
Pelz D.C. et al., 1983	30/M	Venous angioma	NR	Surgery	Vein resection	Pain free
Martin G.B. et al., 1984	NR	Venous angioma	NR	Surgery	Vein ligation	Improved
Isu T. et al., 1985	35/M	Venous angioma	NR	MVD		Pain free
Trost N. et al., 1987	23/M	Venous angioma	NR	MVD		Pain free
Raveau B. et al., 1992	45/F	Venous angioma	NR	Conservative		Partial relief
Mori S. et al., 1994	38/F	Venous angioma	NR	Surgery	Vein ligation	Death
Nagata H. et al., 1995	35/M	Venous angioma (petrosal vein)	Left	MVD	Vein preserved	Pain free
Küker M. et al., 1997	62/M	Venous angioma	NR	Conservative		Improved
Peterson A.M. et al., 2002 (Case 1)	58/M	Venous angioma adjacent to REZ	NR	MVD		Pain free
Peterson A.M. et al., 2002 (Case 2)	59/M	Venous angioma adjacent to REZ	NR	Conservative		Partial relief
Peterson A.M. et al., 2002 (Case 3)	74/M	Venous angioma adjacent to REZ	NR	Conservative		Partial relief
Peterson A.M. et al., 2002 (Case 4)	43/F	Venous angioma adjacent to REZ	NR	Rhizotomy		Pain free
Peterson A.M. et al., 2002 (Case 5)	70/F	Venous angioma adjacent to REZ	NR	MVD		Pain free
Korinth M.C. et al., 2002	35/F	Venous angioma	NR	MVD	Vein preserved	Pain free
Albanese G. et al., 2007	56/M	Venous angioma	NR	MVD		Pain free
Acioly M.A. et al., 2010	57/M	Developmental venous anomaly	NR	Conservative		Pain free
Yamamoto T. et al., 2013	34/F	Venous angioma	Right	MVD		Pain free
Present series (Case 1)	15/F	DVA (cerebellar draining vein)	Left	MVD		Pain free
Present series (Case 2)	38/M	DVA (venous compression; Sindou III)	Right	MVD		Recurrence
Present series (Case 3)	40/F	DVA (transpontine vein)	Right	MVD	Vein preserved	Pain free
Present series (Case 4)	46/M	DVA + chronic transverse sinus thrombosis	Left	MVD	Limited vein coagulation	Pain free; transient edema

Note: adapted from the literature review by M. Samadian et al. (2015) and updated with the present series; M – male; F – female; MVD – microvascular decompression; NR – not reported

Примечание: адаптировано по результатам обзора литературы М. Samadian и соавт. (2015) с дополнением данными настоящей серии наблюдений; М – мужской пол; Ж – женский пол; МВД – микроваскулярная декомпрессия; НД – нет данных

Information about the authors / Сведения об авторах

Pavel I. Trukhachev – Radiologist, Federal Neurosurgical Center; e-mail: p_trukhachev@neuronsk.ru

Elena A. Filimonova – Radiologist, Head of the Department of Radiology, Federal Neurosurgical Center; Teaching Assistant of the Department of Neurosurgery, Novosibirsk State Medical University; ORCID: <https://orcid.org/0000-0002-6696-9071>; e-mail: e.filimonova@alumni.nsu.ru

Трухачев Павел Игоревич – врач-рентгенолог, Федеральный центр нейрохирургии Минздрава России; e-mail: p_trukhachev@neuronsk.ru

Филимонова Елена Андреевна – врач-рентгенолог, заведующая отделением лучевой диагностики, Федеральный центр нейрохирургии Минздрава России; ассистент кафедры нейрохирургии, Новосибирский государственный медицинский университет Минздрава России; ORCID: <https://orcid.org/0000-0002-6696-9071>; e-mail: e.filimonova@alumni.nsu.ru

✉ Автор, ответственный за переписку / Corresponding author